



## Case Study

### A CASE REPORT ON EFFECTIVE MANAGEMENT OF RETAINED PRODUCT OF CONCEPTION THROUGH AYURVEDA REGIMEN

Khushboo Jha<sup>1\*</sup>, K. Bharathi<sup>2</sup>, Sonu<sup>3</sup>, M.S. Anu<sup>4</sup>

<sup>1</sup>PG Scholar, <sup>2</sup>Head of Department, <sup>3</sup>Lecturer, <sup>4</sup>Clinical Registrar, Department of Prasuti Tantra Evam Stri Roga, National Institute of Ayurveda, Jaipur, India.

#### ABSTRACT

The term retained products of conception (RPOC) refers to intrauterine tissue that develops after conception and persists after medical and surgical pregnancy termination, miscarriage, and vaginal or cesarean delivery. Approximately half of the conceptions are not even recognized 10-15% is lost during 1st trimester and additional 2-3% is lost in later pregnancy. The word abortion means expulsion from the uterus of the product of conception before the fetus is viable. This period of viability is different in different views. In modern medicine the period of viability is taken as 7 months. In Ayurveda this abortion is mentioned with the name of *Garbhasrava* or *Garbhapata*. A 30 yr old female patient came to NIA opd with a complaint of heavy bleed continuously since 1 month. On examination it was found, she has taken MTP pill from local clinic. D and C was done though she was getting her bleed continuously. Then, she came to NIA opd for futher management and was given *Dashmool Kwatha*, *Ajmodadi Churna*, *Triphala Guggulu* and *Prataplankeshwar ras* for 7 days. Then the patient was advised for USG which revealed no retained product of conception.

**KEYWORDS:** Abortion, Residual product of conception , D & C, *Dashmoola kwatha*.

#### INTRODUCTION

The term retained products of conception (RPOC) refers to intrauterine tissue that develops after conception and persists after medical and surgical pregnancy termination, miscarriage, and vaginal or cesarean delivery. Patients with RPOC usually presented abdominal pain, bleeding, fever: these clinical symptoms aren't specific, but the early diagnosis is critical for directing clinical management of bleeding and for preventing associated consequences<sup>[1]</sup>. Ultrasonography (US) is useful in the evaluation of RPOC and the diagnosis is supposed on the sonographic appearance of intrauterine echogenic material. Although transvaginal sonographic enhances evaluation for RPOC, the diagnosis is sometimes difficult because necrotic decidua and blood clots may be very difficult to differentiate from RPOC<sup>[2]</sup>. Short term consequences of RPOC include bleeding and infections, while long term consequences include formation of intrauterine adhesions, also defined Asherman's syndrome. So a careful investigation, a management with efficient planning and an accurate follow up are required in patients with retained products of conception to lessen morbidity and to preserve their obstetric outcome. Retained products of conception complicate ~1-5% of all pregnancies. According to one

prospective study, RPOC was present after a third-trimester delivery in around 2.7% of women, whereas it was diagnosed in pregnancies ending during the second and first trimesters in 40% and 17%, respectively. It occurs with greater frequency with: medical termination of pregnancy (MTP), second-trimester miscarriage and placenta accreta. There are different modalities for management of RPOC which consists of surgical intervention, medical treatment, and expectant management depending on the patient's condition. Hyper vascular RPOC's present a clinical challenge as unprepared intrauterine manipulation in the presence of RPOCs with rich blood flow might lead to uncontrollable massive bleeding, potentially requiring an undesired hysterectomy or uterine artery embolisation to preserve the uterus. An accurate and early diagnosis is therefore essential. Among the surgical methods simple D&C is universally accepted. However it is estimated that nearly 20 % of RPOCs have increased vasularities in such cases simple D&C may lead to massive haemorrhage.

According to Ayurveda point of view, incompletely expelled *Ama garbha* troubles woman repeatedly, hence it should be treated by pungent drugs till its complete expulsion.

## Case History

A 30-year-old female, multi gravida with LMP on 1/11/2020 visited the Prasutitantra & Streeroga, O.P.D. NIA Jaipur on 13/01/2021. She came with complaining of bleeding per vagina since one month, associated with generalized debility, fever and abdominal pain. On history taking patient said that she had taken MTP kit on 8/12/2020 (5 weeks of amenorrhoea) as she had already completed her family with three children, so she did not want further pregnancy. Then she had heavy bleeding per vagina after taking MTP pill. Due to continuous bleeding she went to consult doctor and was advised to go through D & C. She underwent the procedure on 27/12/2020. Then after having the procedure, the bleeding was not controlled. After that she went for sonography and came with USG report to Prasuti Tantra and Stri Roga OPD, National Institute of Ayurveda, Jaipur revealing retained product of conception. On examination, general condition of the patient was good.

## Physical Examination

### Ashta Vidha Pariksha

Nadi	72/min
Mutra	5-6 times/day
Mala	Twice /day
Jihwa	Malavrita
Shabda	Samanya
Sparsha	Ushna
Drika	Malina
Aakriti	Sthula

### Dashvidha Pariksha

Prakriti	Vatakaphaja
Vikriti	Madhyam
Sara	Madhyama
Samhanana	Avara
Pramana	Madhyam
Satmya	Mishra ras
Satva	Madhyam
Vaya	Yuvati
Vyayamshakti	Madhyam
Aharashakti	Abhyavarana shakti – madhyam, Jarana shakti – madhyam, Vyayama shakti – Avara

## Systemic Examination

On Systemic Examination, there was no significant abnormality noted.

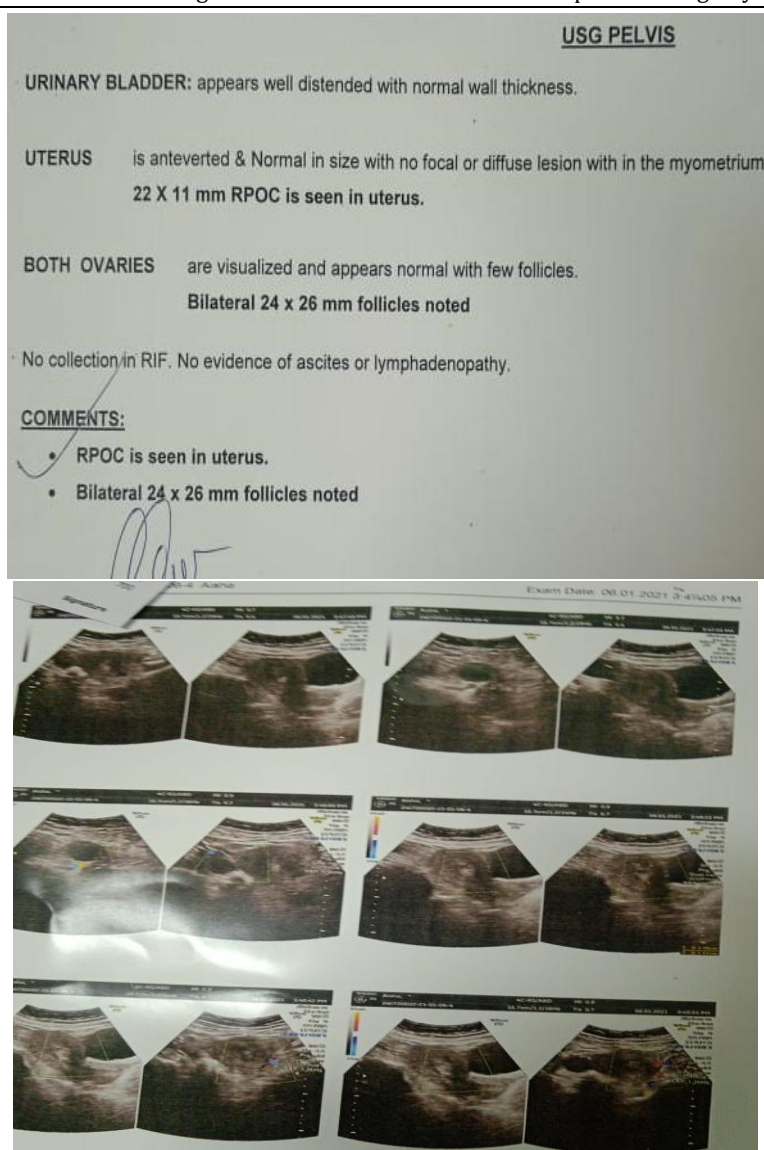
**Investigations:** USG on 6/1/2021

- ❖ **Menstrual History-** Her past menstrual history revealed that her cycle was normal with six days continue bleed associated with clots and mild pain in abdomen and back.
- ❖ Past medical history and Past surgical history was not significant.
- ❖ Personal history of the patient revealed that her appetite, sleep, micturition and bowel habit was normal.

## Clinical Findings

**General examinations:** Built – Normal, Weight – 70 kg, Height-151 cm, BMI- 30.7kg\m<sup>2</sup>, Tongue –Coated, Pallor-Absent , Pulse Rate -72/Min , BP-110/70 Mm Of Hg, Respiration Rate 18/Min , Temp – 98.3F

Per vaginal examination was with-held to avoid undue handling of uterus, considering the situation.



S.no.	Aushadi/Drug	Matra/Quantity	Kalpna/Form	Kala/Dosage	Anupana
1.	<i>Dashmoola kwatha</i>	40 ml	<i>Kashaya</i> /decoction	twice a day	
2.	<i>Ajamodadi churna</i>	3gm	<i>Churna</i> /Powder	<i>twice a day</i>	Lukewarm water
3.	<i>Triphala guggulu</i>	500 mg	<i>Vati</i> /tablet	thrice a day	Water
4.	<i>Prataplankeshwar rasa</i>	500 mg	<i>Vati</i> /tablet	twice a day	Lukewarm water

<i>Triphala guggulu</i> ingredients <sup>[3]</sup>	Latin name
<i>Haritaki</i>	<i>Terminalia chebula</i>
<i>Bibhitaki</i>	<i>Terminalia bellirica</i>
<i>Amalaki</i>	<i>Phyllanthus emblica</i>
<i>Pippali</i>	<i>Piper longum</i>
<i>Guggulu-suddha</i>	<i>Commiphora wightii</i>

<b>Prataplankeshwar ras<sup>[4]</sup></b>	<b>Latin name</b>
<i>Suta (Suddha parada )</i>	Hydrargium (Hg)
<i>Abhraka</i>	Biotite Mica
<i>Gandhaka</i>	Purified sulphur
<i>Maricha</i>	<i>Piper nigrum</i>
<i>Vanyotpala bhasma</i>	-----
<i>Visa (Suddha vatsnabha)</i>	<i>Aconitum ferox</i>

<b>Ajmodadi churna<sup>[5]</sup></b>	<b>Latin name</b>
<i>Ajmoda</i>	<i>Trachyspermum ammi</i>
<i>Vidanga</i>	<i>Embelia ribes</i>
<i>Saindhav Lavana</i>	Rock salt
<i>Devadaru</i>	<i>Cedrus deodara</i>
<i>Citraka</i>	<i>Plumbago zeylanica</i>
<i>Pippalimula</i>	<i>Piper longum</i>
<i>Satapusp</i>	<i>Anethum graveolens</i>
<i>Pippali</i>	<i>Piper longum</i>
<i>Maricha</i>	<i>Piper nigrum</i>
<i>Pathaya</i>	<i>Terminalia chebula</i>
<i>Vrddhadaru</i>	<i>Argyreia nervosa</i>
<i>Nagara</i>	<i>Zingiber officinale</i>

<b>Dashmoola kwatha churna<sup>[6]</sup></b>	<b>Latin name</b>
<i>Salparni</i>	<i>Desmodium gangeticum</i>
<i>Prisniparni</i>	<i>Uraria picta</i>
<i>Brihati</i>	<i>Solanum indicum</i>
<i>Kantakari</i>	<i>Solanum xanthocarpum</i>
<i>Gokshura</i>	<i>Tribulus terrestris</i>
<i>Bilva</i>	<i>Aegle marmelos</i>
<i>Agnimantha</i>	<i>Premna serratifolia</i>
<i>Syonaka</i>	<i>Oroxylum indicum</i>
<i>Kasmari (Gambhari)</i>	<i>Gmelina arborea</i>
<i>Patala</i>	<i>Stereospermum suaveolens</i>
<i>Prakshepa dravya: pippali churna</i>	<i>Piper longum (Prakshepa dravya)</i>

## RESULT

Patient was given above regimen for 7 days. Then she visited NIA PTSR OPD with her USG Report. The sonography reports revealed that there was no evidence of residual product with normal study scan on 20/1/2021.

SONOGRAPHY LOWER ABDOMEN	
U.BLADDER	- Urinary bladder is normal in size, shape and wall thickness.
UTERUS	- Uterus size - 75 x 44 x 30 mm in diameter. Uterus is anteverted and smooth. Parenchymal echotexture appear normal. Endometrium is central, linear with normal thickness. <b>No evidence of GS/RPOC in present study.</b>
OVARIES	- Right ovary size - 21 x 16 mm. Left ovary size - 28 x 19 mm. Both ovaries are normal in size, shape and echotexture.

### Probable Mode of Action of the Drugs

✚ <i>Dashmoola kwatha</i>	Anti-inflammatory, antipyretic, anti-bacterial, diuretic, haemostatic, analgesic, rejuvenative, induce contraction of the uterus.
✚ <i>Ajmodadi churna</i>	Anti-inflammatory, analgesic, antibacterial.
✚ <i>Triphala guggulu</i>	Anti-bacterial, anti-fungal, anti-septic, anti-oxidant, anti-inflamamtory
✚ <i>Prataplankeshwar rasa</i>	Anti-bacterial, Anti-pyretic.

### DISCUSSION

In the present case effective management of retained product of conception was brought about by the Ayurvedic formulations having *Lekhaniya, Ushna, Ruksha, Tikshna, Vatanuloman, Garbhasaya sodhana* which facilitates complete evacuation of the products of conception with efficient contractions, thereby even minimising the blood loss. *Dashmola Kwatha* acts as uterine tonic and uterine detoxifier.<sup>[7]</sup> *Ajmodadi churna* is one of the best *Amapachana* (digestion of *Ama*) drug in Ayurveda classics. So, the retained product of conception acts as *Visha/ Ama/* toxins to the body also hampers the bodily *Dhatu*s. So it also helps in digestion of *Ama*. *Ajmodadi churna* has anti-inflammatory effect.<sup>[8]</sup> It consists of *Terminalia chebula* which exhibits anti-viral, antibacterial and wound healing property. *Triphala guggulu* balances all the three *Doshas* in the body and is extremely beneficial in removing toxins. It is a potent detoxifier. *Prataplankeshwar rasa* cleanses uterus and eliminates toxins from the body. It is also equally effective in fever, infection. These drugs cause *Shoshana* of *Dushita Dosh*a, *Dhatu* and *Kleda*<sup>[9]</sup>, thereby normalizing the *Agni, Dosh*a, *Dhatu* and thus collectively facilitate early recovery of the patient. The above mentioned drugs also had anti-inflammatory, analgesic, anti-microbial actions which supported in relieving the pain and in preventing further infections and complications.

### CONCLUSION

This case of retained product of conception was effectively managed by Ayurvedic drugs. There was expulsion of retained product of conception with

complete cessation of pain. Bleeding was also stopped without requiring any invasive procedure. Patient did not get any complications. Misoprostol is the common drug used by modern practitioners for abortion. Misoprostol is acting as an alternative to surgical therapy. But to some extent, if misoprostol fails, surgical intervention in the form of curettage has to be done to expel the products of conception. Misoprostol, medical management have always the risk related to bleeding p/v, pain, mild fever, incomplete evacuation, blood coagulation disorders and side effects due to anesthesia. Infections, uterine perforation, cervical laceration etc. complications may also be seen post D&E due to instrumentation<sup>[10]</sup>. So, it is high time to go through the Ayurvedic formulations. As we can say management of retained product of conception with Ayurvedic drugs is safe and also economical. Patient had not to stay a longer time in hospital also. This is a single case study, more research to be done in large sample in upcoming days.

### REFERENCES

- Sellmyer MA, Desser TS, Maturen KE, Jeffrey RB Jr, Kamaya A. Physiologic, histologic, and imaging features of retained products of conception. *Radiographics*. 2013; 33: 781-96.
- Ustunyurt E, Kaymak O, Iskender C, Ustunyurt OB, Celik C, Danisman N. Role of transvaginal sonography in the diagnosis of retained products of conception. *Arch Gynecol Obstet*. 2008; 277: 151-4.

3. Anonymous. The Ayurvedic Formulary of India, Govt of India, Dept of Ayush, Delhi e-book vol 1, pp-176
4. Anonymous. The Ayurvedic Formulary of India, Govt of India, Dept of Ayush, Delhi e-book vol II, pp-208
5. Anonymous. The Ayurvedic Formulary of India, Govt of India, Dept of Ayush, Delhi e-book vol 1, pp 308
6. Anonymous. The Ayurvedic Formulary of India, Govt of India, Dept of Ayush, Delhi e-book vol 1, pp 212
7. Dr.Jagdev Singh <https://www.ayurtimes.com/dashmool-dashamoola-dashamula/>
8. H. N. Aswatha Ram, Neeraj K. Sriwastava, Inder K. Makhija, and C. S. Shreedhara Anti-inflammatory activity of Ajmodadi Churna extract against acute inflammation in rats J Ayurveda Integr Med. 2012 Jan-Mar; 3(1): 33-37.
9. Hari Sadasiva Shastri Navre, Editor. Ashtanga Hrudayam of Vagbhata, Sharira Sthana, Chapter 2, Verse 13, Chaukhambha Sanskrit Sansthan, Varanasi, Reprint 2012, p. 379.
10. Hiralal Konar, Editor, DC Dutta, Author, Textbook of Obstetrics, 4th Edition, New Central Book Agency Pvt Limited Publication, Kolkata, reprint 2007, p. 535.

**Cite this article as:**

Khushboo Jha, K. Bharathi, Sonu, M.S. Anu. A Case Report on Effective Management of Retained Product of Conception Through Ayurveda Regimen. International Journal of Ayurveda and Pharma Research. 2021;9(2):23-28.

**Source of support: Nil, Conflict of interest: None Declared**

**\*Address for correspondence**

**Dr. Khushboo Jha**

3rd Year PG Scholar,  
Department of Prasuti Tantra Evam  
Stri Roga,  
National Institute of Ayurveda,  
Jaipur.  
Email: [drkhushboojha926@gmail.com](mailto:drkhushboojha926@gmail.com)

Disclaimer: IJAPR is solely owned by Mahadev Publications - dedicated to publish quality research, while every effort has been taken to verify the accuracy of the content published in our Journal. IJAPR cannot accept any responsibility or liability for the articles content which are published. The views expressed in articles by our contributing authors are not necessarily those of IJAPR editor or editorial board members.

