



Case Study

LOCAL AND INTERNAL THERAPEUTIC APPROACH IN THE MANAGEMENT OF *BHAGNA* WITH SPECIAL EMPHASIS TO MICRO-TRABECULAR FRACTURES OF THE HUMERUS HEAD TO AVERT THE INTENDED SURGERY

Kashikar Prathamesh Pradeep^{1*}, Babar Sanjay Chandrakant²

*¹PG Scholar, ²Professor, Department of Shalyatantra, Dr. D. Y. Patil College of Ayurved & R.C., Pimpri, Pune, Dr. D.Y. Patil Vidyapeeth (Deemed to be University), Pimpri, Pune, Maharashtra, India.

Article info

Article History:

Received: 18-06-2023

Revised: 07-07-2023

Accepted: 23-07-2023

KEYWORDS:

Bhagna, Micro-trabecular humerus fracture, Sports injuries, *Bhagna Chikitsa*.

ABSTRACT

Sports have become more and more popular in our country, which has led to an increase in traumatic injuries whose aetiology is linked to sports injuries. When he described *Bhagna Chikitsa* (management of fractures), the renowned *Acharya Sushruta* properly identified injuries, signs and symptoms, local and internal therapies, disorders related to bones, and optimal bone healing features. *Acharya Sushruta* developed the fundamental principles of *Bhagnasthapna* (reduction of fractures), *Sthirikarna* (stabilisation), *Anchana* (traction), *Bandhana* (splints), *Lepa* (pargeting), and *Parisheka* (douching) in order to treat these injuries while they are still active and to rehabilitate the joint to prevent subsequent problems like joint stiffness. Trauma management has a long history that extends back to the Vedic era and is still useful today. In an effort to avoid the desired surgery, the case report of a diagnosed case of *Bhagna* of a 25 year young male with special reference to the micro-trabecular fracture of the humerus head that follows, further discusses the *Sushruta Samhita's* all-encompassing approach to treating *Bhagna* by utilising internal drugs and local remedies. The treatment of micro-trabecular fractures only entails calcium supplements, NSAIDs, and later micro-bone grafting surgery. **Purpose of Study:** The key objective of the study is to effectively manage a post-traumatic micro-trabecular fracture of the humerus head refrain from performing the preferred micro-bone grafting surgery using local treatments and internal medications from the *Sushruta Samhita*. **Observation and Conclusion:** Within two days, the patient saw a considerable reduction in discomfort, and by the time the therapy was over, the patient was completely symptom-free, had no shoulder stiffness, and had experienced a large increase in the AROM (Active Range of Motion) of the shoulder joint.

INTRODUCTION

The ancient medical system of Ayurveda contains a wide range of expert fields that, in addition to the basic prevention and management of diseases, may treat serious illnesses. *Asthibhagna* (fractures) is one such field that deals with severe musculoskeletal injuries.

Bony fracture is one of the serious conditions that can develop after a body injury. According to Ayurveda, a fracture is known as *Bhagna* and can be

brought on by many physical traumas such as slippage, high pressure, rapid jerks, falling from heights, alike same [1]. Injury to the joints is known as *Sandhi Bhagna*, whereas injury to the bones section is known as *Kanda Bhagna*. *Sandhighata* is another name for injury to tissues other than joints. The *Bhagna* affects not just bones but also muscles, ligaments, joints, etc [2]. The ability of the *Asthi* (bones), which are said to be the body's most important structural support system, can only be restored by *Bhagna chikitsa*.

The treatment of fracture based upon the three fundamental principles which are as follows [3]:

- *Bhagna Sthapana*: (Reduction in severity)
- *Bhagna Sthirikara*: (Immobilization; restriction in movement)
- *Punaha cheshta prasara*: (Rehabilitation)

Access this article online

Quick Response Code



<https://doi.org/10.47070/ijapr.v11iSuppl3.2863>

Published by Mahadev Publications (Regd.)
publication licensed under a Creative
Commons Attribution-NonCommercial-
ShareAlike 4.0 International (CC BY-NC-SA 4.0)

By employing *Kavalika*, *Kushika* and *Ghrita* in addition to putting the bone in its original anatomical position, *Bhagna sthapana* can be performed. In order to prevent future displacement and promote bone reunification, the bone needs to be stabilised. The *Chikitsa* of *Bhagna* employs a number of techniques. These methods, such as *Lepana*, *Bandhana*, *Parisechan* and *Pradeha* among others, provide symptomatic alleviation and promote early bone fracture repair. *Lepana* refers to applying a medicinal ointment to the site of the fracture. *Manjishtha*, *Raktachandana*, *Shatadhauta Ghrita* and *Madhuka* among other ingredients, can be used to make *Lepana*^[4]. A bandage or plaster that may be changed after a few days is referred to as a *Bandhana*.

Generally speaking, the plaster was modified in accordance with the *Doshas* present at the broken site. The ideal *Bandha* is one that is neither too loose nor too tight. The *Bandhana* aids in the healing of *Shopha*, *Ruk*, *Paaka* and other injuries at the scene^[5]. Pouring the decoctions over the *Bhagna* site is known as *Parisechana*. It is also possible to employ *Vata* pacifying medications in addition to *Sukhoshna chakrataila*^[11]. *Pradeha* is the Sanskrit term for applying viscous ointment to the injured area. Similar to *Seka*, continuous *Lepana* should be conducted when using medicines with a cooling effect. All of these methods aid in the relief of symptoms and enhance the healing process.

According to contemporary medicine, there are three stages to the treatment of fractures. Splinting, ice therapy, compression, and elevation are used to stop movement of the part during the initial stage. This aids in minimising pain, oedema, and movement of the fractured component. The reduction and immobilisation phases are the first and second phases, respectively^[7]. The third phase focuses on the rehabilitation of the broken component using various activities. However, a micro-trabecular fractures of the humerus head requires conservative treatment, such as cold fomentation, rest, oral analgesics, physical therapy, or a future procedure involving micro-bone grafting^[8]. In this case study, we used both internal and local therapies to treat a patient who had a micro-trabecular fractures of the humerus head in order to prevent the need for surgery and limit the duration of analgesic use.

Therefore, this regimen can be applied in sports medicine in the future after more clinical

investigations are completed for the treatment of acute disease phases and the rehabilitation of desired body parts without any negative side effects.

AIM

To evaluate the efficacy of therapeutic regimen that includes local and internal treatment as mentioned by *Acharya Sushruta* in the management of *Bhagna* w.s.r. to Micro-Trabecular Fracture of the Humeral Head.

OBJECTIVES

- To avoid the desired micro-bone grafting surgery.
- To restrict swelling at shoulder joint and acquaint relief from 'Painful Arc Syndrome' in the acute phase.
- To restore the normal range of motion of shoulder joint with prevention of post-traumatic shoulder joint stiffness and muscle wasting.

A Case Report

Present case report reveals a young male patient of 25 years of age, who had trauma by fall on outstretched right shoulder while playing cricket 2 days ago and presented with symptoms like pain, swelling and was unable to do any of the rotational movements of right shoulder. He had maximum pain while lying down on right lateral position at night for which had consumed NSAID's as prescribed by his family doctor but had temporary relief. So, for further management he visited the Shalyatantra OPD.

General and systemic examination disclosed no such notable findings.

History of Present Illness

Patient was ostensibly fit two days ago, then while playing outdoor cricket fell on outstretched right shoulder. He presented with complaints of pain, unable to do right shoulder movements, swelling so consulted a family doctor and took NSAID's but had no relief so visited the Shalyatantra OPD of Dr. D. Y. Patil College of Ayurveda and Research Centre, Pimpri, Pune-18 for further management.

History of Past Illness

He had no history of any major illness previously and no relevant family history.

Personal History: Addiction-none, occupation-laboratory technician, appetite-normal, sleep-disturbed (due to pain), bowel-regular, micturition-normal, allergy-none.

Table 1: Atura bala pramana parikshana (examination of strength of patient)

Prakriti (Body constitution)	Vatapittaj
<i>Sara</i> (Tissue quality)	<i>Madhyam</i> (average)
<i>Samhanana</i> (body built)	<i>Madhyam</i> (average)
<i>Pramana</i> (anthropometry)	Weight- 62kg, height- 165cm

Satmya (adaptability)	Madhyam (average)
Satva(mental strength)	Madhyam (average)
Aharashakti (food intake and digestion capacity)	Abhyavaran- average, Jarana—7 hours
Vyayamashakti (exercise capacity)	Madhyam (average)
Vaya (age)	Yuvavastha (adult)
Desha (habitat)	Sadharana

Examination of Right Shoulder Joint [9]

Inspection

Mild swelling noted over posterior aspect of right shoulder joint.

No specific shortening of the right limb noted.

No bruising noted over impacted area.

Palpation

Severe Tenderness with withdrawal present at posterior aspect shoulder joint.

No specific bony deformity noted by palpation.

Crepitation present

Pain elicited by rotation movement of right shoulder joint.

Table 2: Assessment of objective parameter

S.No.	Observation Parameter	Gradation
1.	Swelling	Grade 1 (Swelling present)
2.	Pain (VAS Scale)	7/10
3.	Tenderness	Grade 2 (Tenderness to palpation with grimace)
4.	Crepitation	Grade 1 (crepitation present)

Table 3: Assessment gradation

S.No	Observation	Parameter	Gradation
1.	Swelling	Swelling absent	Grade 0
		Swelling present	Grade 1
2.	Pain (VAS Scale)	According to score marked by patient	0-10
3.	Tenderness	No tenderness	Grade 0
		Tenderness to palpation without grimace	Grade 1
		Tenderness to palpation with grimace	Grade 2
		Tenderness with withdrawal	Grade 3
		Withdrawal to noxious stimuli	Grade 4
4.	Crepitation	Crepitation absent	Grade 0
		Crepitation present	Grade 1

Table 4: AROM (Active range of motion) of right shoulder revealed following findings (Before treatment)

Parameters	ROM (In Degrees)
1. Forward Flexion	0-120
2. Hyper-Extension	0-20
3. Abduction	0-100
4. Adduction	0-100
5. Internal Rotation	0-10
6. External Rotation	0-20

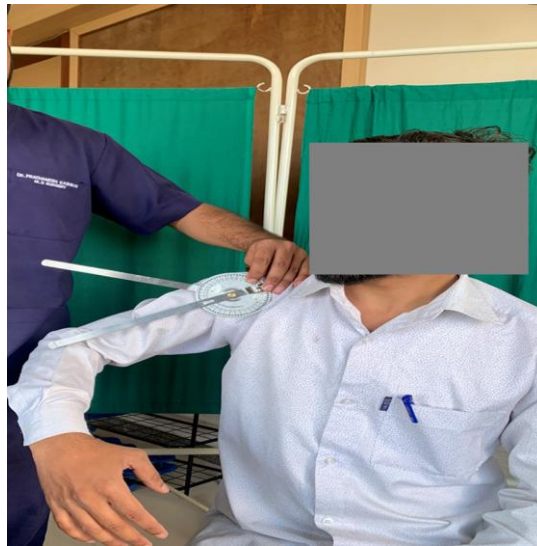

Figure 1: Measuring the range of motion of right shoulder with goniometer

Radiological Investigations

MRI of right shoulder joint

1. Micro-trabecular fractures seen involving humeral head posteriorly.
2. Mild fluid in sub-coracoid bursa.
3. Mild surrounding soft tissue oedema.
4. No obvious rotator cuff tendons tear noted.

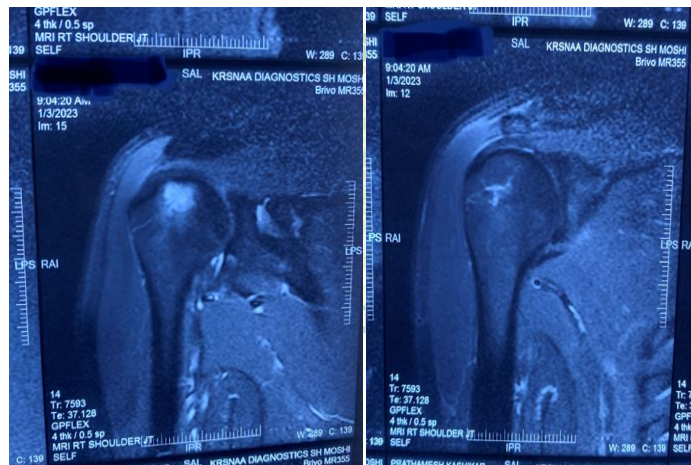


Figure 2: MRI film of right shoulder describing micro-trabecular fracture of humerus head

Therapeutic Regimen

Concerned research presents a combination internal and local treatment for *bhagna* (Micro-trabecular fracture of Humerus head) that includes the following: [10]

Table 5: Local and Oral Treatment Regimen

S. No.	Therapeutic Focus	Duration
1.	Active Management i. <i>Parisheka</i> (douching) with <i>Sheeta</i> (cold) <i>Nyagrodhadhi gana qwath</i> (decoction) ii. <i>Manjishthadi lepa</i> (pargeting) iii. <i>Kusha-bandhana</i> (shoulder-binder splint)	First five days
2.	Subsequent Management i. <i>Parisheka</i> (douching) with warm <i>Tila Taila</i> ii. <i>Manjishthadi lepa</i> (pargeting) iii. <i>Kusha-bandhana</i> (shoulder-binder splint)	From sixth day to 28 th day
3.	Internal medications Cap. <i>Gandha Tailam</i> (1 capsule thrice a day with milk) Tab. <i>Lakshadi Guggul</i> (2 tablets thrice a day with milk)	For 28 days

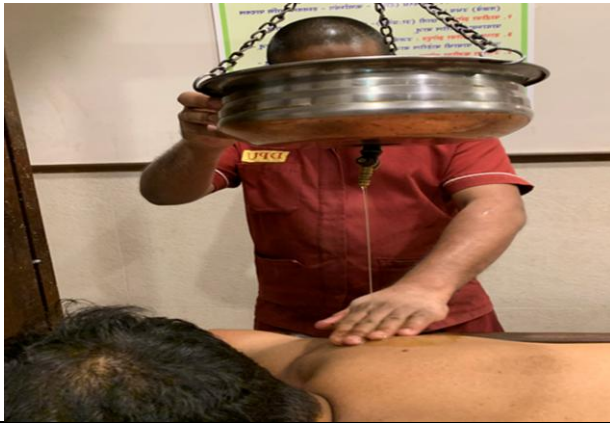

Figure 4: Parisheka (Douching) with Sheeta (cold) Nyagrodhadhi gana qwath (Decoction)

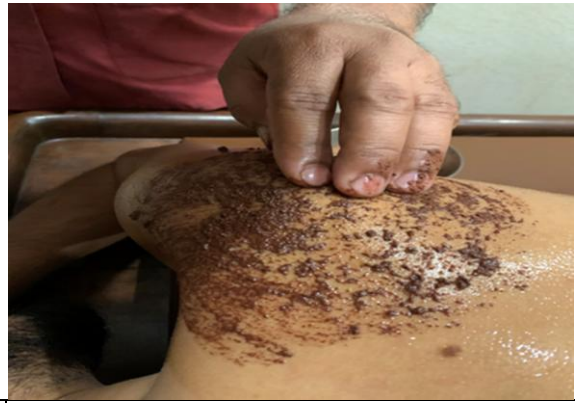

Figure 5: Manjishthadi lepa (Pargeting)

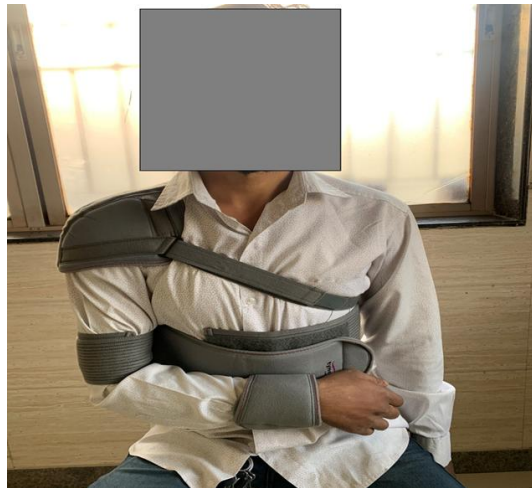

Figure 6: Kusha-bandhana (Shoulder-binder splint)

OBSERVATION AND RESULT

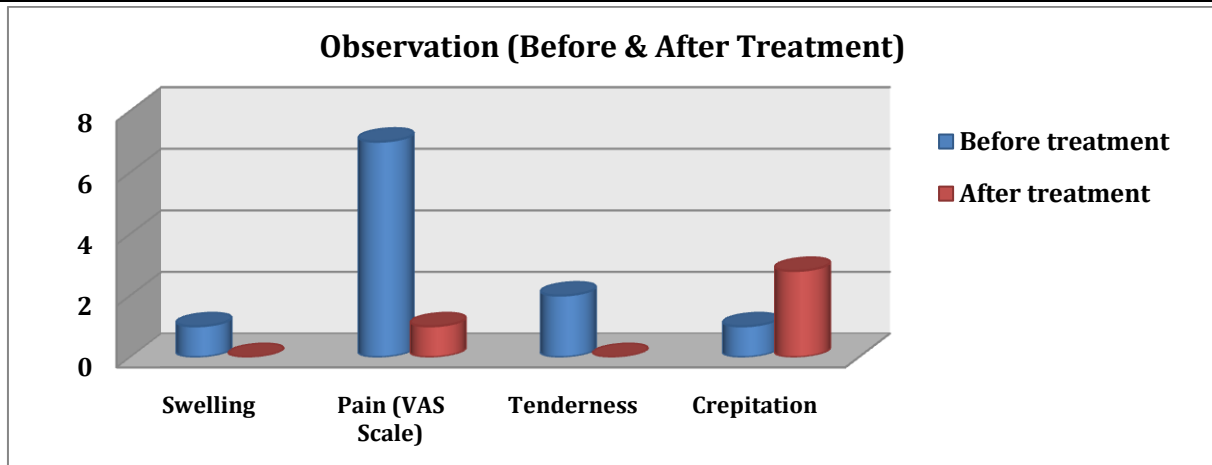
After Five days: Patient had significant relief in pain with no swelling or bruising visible.

At the end of treatment (28th Day): Complete relief from symptoms with no stiffness at shoulder joint.

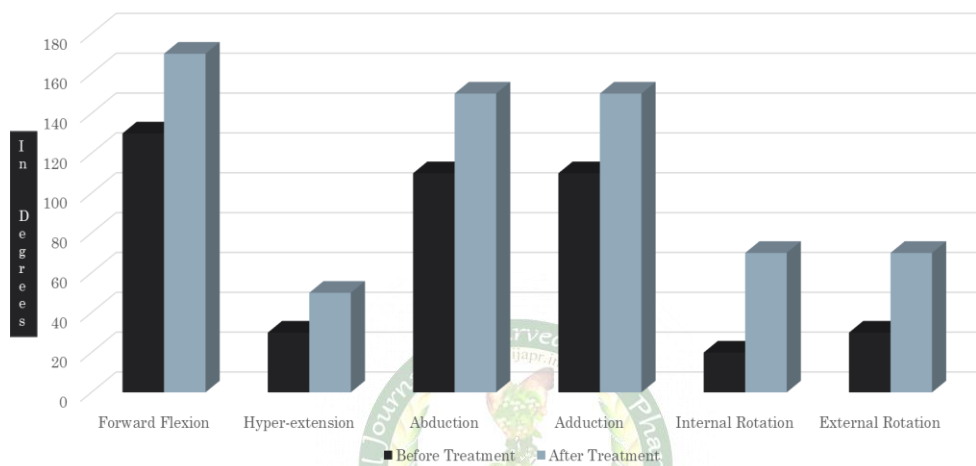
After treatment significant increase in the AROM of right shoulder joint was observed without muscle wasting.

Table 6: Observation (Before and after treatment)

S.No.	Observation Parameter	Gradation (Before treatment)	Gradation (After treatment)	
1.	Swelling	Grade 1 (swelling present)	Grade 0 (swelling absent)	
2.	Pain (VAS Scale)	7/10	1/10	
3.	Tenderness	Grade 2 (tenderness to palpation with grimace)	Grade 0 (no tenderness)	
4.	Crepitation	Grade 1 (crepitation present)	Grade 0 (crepitation absent)	
5.	ROM of right shoulder	1. Forward Flexion	0-120	0-160
		2. Hyper-Extension	0-20	0-40
		3. Abduction	0-100	0-140
		4. Adduction	0-100	0-140
		5. Internal Rotation	0-10	0-60
		6. External Rotation	0-20	0-40



Graph 1: Graphical representation of observation (before and after treatment)



Graph 2: Graphical representation of range of motion of right shoulder joint (before and after treatment)

DISCUSSION

Acharya Sushruta did an outstanding task of describing *Bhagna* in his classical literature, including its signals of fracture healing, types, diagnoses, and treatments.

In order to get over the stage of haematoma during fracture healing, the idea behind using *Sheeta parisheka* is to aid vasoconstriction, which further inhibits swelling along with relief from pain and bruises [11]. This is done for 5 days.

In addition, *Bandha* (splint) aids in restricting joint motion, which helps to relieve pain and prevent further fracture progression as well as harm to adjacent skin, soft tissues, and neurovascular components [12].

The use of *Lepa* is beneficial because it has *Rakta-prasadan*, anti-inflammatory, analgesic, fracture healing, and bone and joint stabilising effects [13].

Ushna parisheka with warm *Chakra tila taila* strongly contributes to the stages of bone remoulding and soft and bony callus development during fracture healing[14]. Due to components like *Bruhan*, *Prinan* and *Mamsasairiya*, warm tail is used to improve vascularization and has analgesic characteristics with the prevention of muscle wasting and joint stiffness [15].

By raising bone mineral density and initiating the fracture healing process, eliminates vitiated *Vata dosha* and is also useful for treating the kings, *Gandha taila*[16] and *Lakshadi Guggul* have demonstrated fracture healing qualities[17].

CONCLUSION

Based on the clinical findings, it can be said that *Acharya Sushruta's* all-encompassing method of treating *bhagna*, a micro-trabecular fracture of the humeral head, yields notable results by reducing uncomfortable arc signs, reducing pain, and restoring shoulder range of motion within 28 days of the trauma, which prevents the need for surgery.

It is the best since it is simple to execute, eliminates hematoma formation, swelling, and repercussions including joint stiffness and muscle wasting, as well as being cost-effective. No, as such detrimental effects were detected.

Further Scope of Study

- Futuristic clinical trial with more sample size is though needed to gain confirmatory outcomes.
- Active management of sport's injury without adverse effects.

- This treatment modality can be applied on various types of fractures along with those occurring in geriatric and pediatric age group where surgery is not possible.
- Avoidance of surgery in simple fractures can be more affordable in terms of financial concerns in low-income groups.

REFERENCES

1. Maharshi Sushruta, Shushurta Samhita, part-I, Ayurveda Tatwa Sandeepika Hindi Commentary, edited by Kaviraj Ambika Dutta Shastri Nidanasthana, Bhagnaadhaya Chapter-15. bhagna chikitsasthan Edition-13. Varanasi: 3 Chaukhamba Sanskrit Sansthan; 2002. p.377, shloka-3.
2. Maharshi Sushruta, Shushurta Samhita, part-I, Ayurveda Tatwa Sandeepika Hindi Commentary, edited by Kaviraj Ambika Dutta Shastri Nidanasthana. Bhagnaadhaya Chapter-15. bhagna chikitsasthan Edition-13. Varanasi: 3 Chaukhamba Sanskrit Sansthan; 2002. p.377, shloka-4, 5.
3. Maharshi Sushruta, Dr.Anantram Sharma, edited with 'sushrutvimarsini' Hindi commentary, Sushrut samhita, Part-2, Chikitsasthan, Chapter-3, Bhagnanam chikitsitam adhayaya, Chaukhamba surbharati prakashan, Varanasi, p.192-193, shloka-18,19.
4. Maharshi Sushruta, Dr.Anantram Sharma, edited with 'sushrutvimarsini' Hindi commentary, Sushrut samhita, Part-2, Chikitsasthan, Chapter-3, Bhagnanam chikitsitam adhayaya, Chaukhamba surbharati prakashan, Varanasi, p.189, shloka-7.
5. Maharshi Sushruta, Dr.Anantram Sharma, edited with 'sushrutvimarsini' Hindi commentary, Sushrut samhita, Part-1, Sutrasthan, Chapter-18, Vranalepanbandhavidhi adhayaya, Chaukhamba surbharati prakashan, Varanasi, p.152, shloka 3.
6. Maharshi Sushruta, Dr.Anantram Sharma, edited with 'sushrutvimarsini' Hindi commentary, Sushrut samhita, Part-2,Chikitsasthan, Chapter-3, Bhagnanam chikitsitam adhayaya, Chaukhamba surbharati prakashan, Varanasi, p.190, shloka-11.
7. J Maheshwari, Vikram A Mhaskar, Essential Orthopaedics, Chapter-2, Anatomy of Bone, Fracture Healing, Jaypee Broters Medical Publishers, New Delhi, p. 10-11.
8. J Maheshwari, Vikram A Mhaskar, Essential Orthopaedics, Chapter-13, Injuries around the shoulder and fracture of Humerus, Jaypee Broters Medical Publishers, New Delhi, p. 90.
9. J Maheshwari, Vikram A Mhaskar, Essential Orthopaedics, Examination of the shoulder, Jaypee Broters Medical Publishers, New Delhi, p. 350-351.
10. Maharshi Sushruta, Dr.Anantram Sharma, edited with 'sushrutvimarsini' Hindi commentary, Sushrut samhita, Part-2, Chikitsasthan, Chapter-3, Bhagnanam chikitsitam adhayaya, Chaukhamba surbharati prakashan, Varanasi, p.199-203.
11. Maharshi Sushruta, Dr.Anantram Sharma, edited with 'sushrutvimarsini' Hindi commentary, Sushrut samhita, Part-2, Chikitsasthan, Chapter-3, Bhagnanamchikitsitam adhayaya, Chaukhamba surbharati prakashan, Varanasi, p.193, shloka-20.
12. Maharshi Sushruta, Dr.Anantram Sharma, edited with 'sushrutvimarsini' Hindi commentary, Sushrut samhita, Part-1, Sutrasthan, Chapter-18, Vrana lepanbandhavidhi adhayaya, Chaukhamba surbharati prakashan, Varanasi, p.152, shloka 4.
13. Maharshi Sushruta, Dr.Anantram Sharma, edited with 'sushrutvimarsini' Hindi commentary, Sushrut samhita, Part-1, Sutrasthan, Chapter-18, Vrana lepanbandhavidhi adhayaya, Chaukhamba surbharati prakashan, Varanasi, p.153, shloka 6.
14. Maharshi Sushruta, Dr.Anantram Sharma, edited with 'sushrutvimarsini' Hindi commentary, Sushrut samhita, Part-2, Chikitsasthan, Chapter-3, Bhagnanam chikitsitam adhayaya, Chaukhamba surbharati prakashan, Varanasi, p.190, shloka-11.
15. Maharshi Sushruta, Dr.Anantram Sharma, edited with 'sushrutvimarsini' Hindi commentary, Sushrut samhita, Part-1, Sutrasthan, Chapter-45, Drava dravyavidhir adhayaya, Chaukhamba surbharati prakashan, Varanasi, p.368.
16. Maharshi Sushruta, Dr.Anantram Sharma, edited with 'sushrutvimarsini' Hindi commentary, Sushrut samhita, Part-2, Chikitsasthan, Chapter-3, Bhagnanam chikitsitam adhayaya, Chaukhamba surbharati prakashan, Varanasi, p.201-202, shloka-57-66.
17. Prof.Dr.Siddhinandan Mishra, edited with 'siddhiprada' Hindi commentary, Bhaishajya Ratnavali, Kaviraj Shri Govindadas Sen, Chapter-49, Bhagna roghadhikara, Chaukhamba Surbharati Prakashan, Varanasi, p.833-834.

***Address for correspondence**
Dr. Kashikar Prathamesh Pradeep
Post Graduate Scholar
Department of Shalyatantra,
Dr. D. Y. Patil College of Ayurved &
R.C., Pimpri, Pune, Dr. D.Y. Patil
Vidyapeeth (Deemed to be
University), Pimpri, Pune,
Maharashtra.
Email:
prathameshkashikar01@gmail.com
Phone: 7767898627

Cite this article as:

Kashikar Prathamesh Pradeep, Babar Sanjay Chandrakant. Local and Internal Therapeutic Approach in the Management of Bhagna with special Emphasis to Micro-Trabecular Fractures of the Humerus Head to avert the Intended Surgery. International Journal of Ayurveda and Pharma Research. 2023;11(Suppl 3):44-50.

<https://doi.org/10.47070/ijapr.v11iSuppl3.2863>

Source of support: Nil, Conflict of interest: None Declared